17th ANNUAL NATIONAL CLINICAL CONFERENCE

ABSTRACTS

Baltimore, MD
September 6-8, 2018

APWCA
AMERICAN PROFESSIONAL WOUND CARE ASSOCIATION
apwca.org

AMERICAN PROFESSIONAL
WOUND CARE ASSOCIATION

Proceedings of the 17th Annual
National Clinical Conference

ABSTRACTS

September 6-8, 2018

Poster abstracts available
for viewing in the Exhibit Hall.

139B James Comeaux Rd | Suite 555 | Lafayette, LA 70508
337.541.2240 | apwca.org

TABLE OF CONTENTS

	ORAL ABSTRACT PRESENTATION SCHEDULE	04
1.	OMEGA-3 RICH FISH SKIN FOR HEALING OF CHRONIC WOUNDS IN THE PRIVATE OFFICE	06
2.	MULTISPECTRAL OXYGENATION IMAGING ASSISTED WOUND DEBRIDEMENT - DIRECTING THOROUGH DEBRIDEMENT AND PREDICTING EFFICACY OF CELLULAR TISSUE PRODUCTS	07
3.	PINCH GRAFTING	08
4.	HEALTH CARE EXPERIENCES OF A CHRONIC WOUND PATIENT: FACTORS THAT MAY PROMOTE AND HINDER WOUND HEALING	09
5.	CHARACTERISTICS, MANAGEMENT, AND OUTCOMES OF PATIENTS WITH SURGICAL WOUNDS REFERRED TO AN INTERPROFESSIONAL WOUND CARE TEAM: A RETROSPECTIVE COHORT STUDY	10
6.	A NOVEL APPROACH TO NEGATIVE PRESSURE WOUND THERAPY- USE OF A HIGH SUCTION CAPILLARY DRESSING TO IMPROVE WOUND HEALING	11
7.	WHEN HEALING IS NOT THE GOAL	12
8.	ONE SIZE DOES NOT FIT ALL	13
9.	APPLICATION OF CONTINUOUS EXTERNAL TISSUE EXPANDER (DERMACLOSE) FOR DELAYED CLOSURE OF LOWER EXTREMITY WOUND FOLLOWING COMPARTMENT SYNDROME FASCIOTOMY: A CASE REPORT	14
10.	BLOOD FLOW REALLY DOES MATTER	15
11.	SURGICAL OFF-LOADING HEALS DIABETIC WOUNDS	16
12.	AGGRESSIVE CONSERVATIVE WOUND CARE: HEAL WOUNDS, PREVENT AMPUTATION	17
13.	COST EFFECTIVENESS OF WOUND TREATMENT WITH FISH SKIN - RESULTS OF A PROGNOSTIC STUDY	18
14.	FISH SKIN GRAFTS-OMEGA3 FATTY ACIDS ARE A SOURCE FOR THE SPECIALIZED PRO-RESOLVING MEDIATORS THAT DRIVE INFLAMMATION RESOLUTION	19
15.	DOUBLE-BLIND, PROSPECTIVE, RANDOMIZED CLINICAL TRIAL ON 170 ACUTE WOUNDS SHOWS SIGNIFICANTLY FASTER HEALING RATE WITH INTACT FISH SKIN COMPARED TO HUMAN AMNIOTIC MEMBRANE	21
16.	A NEW APPROACH IN THE MANAGEMENT OF CHRONIC DIABETIC FOOT ULCERS: A REPORT ON THE USE OF A COLLAGEN WOUND CONTACT LAYER WITH NEGATIVE PRESSURE WOUND THERAPY	23
17.	THE COST AND EFFICACY OF REGENERATIVE WOUND PRODUCTS	24

18.	THE HEALTHY FOOT SCREEN: A PILOT OF NOVEL ASSESSMENT TOOL FOR COMMON CLINICAL FOOT ABNORMALITIES	25
19.	AN INVESTIGATION OF WOUND SURFACE PH AND BACTERIAL BURDEN	27
20.	UNIQUE PROPERTIES OF OXYGENATED COMPOSITE DRESSING PROVIDES SUPERIOR PRESSURE REDISTRIBUTION	28
21.	NOVEL UTILIZATION OF NEAR INFRARED SPECTROSCOPY (NIRS) IMAGING IN DEMONSTRATING THE CLINICAL EFFICACY OF ARTERIAL ENDOVASCULAR INTERVENTION	29
22.	CAN NEAR INFRARED SPECTROSCOPY (NIRS) REPLACE TRANSCUTANEOUS OXIMETRY IN THE CLINICAL MANAGEMENT OF COMPROMISED WOUND?	31
23.	THE INCIDENCE OF DIABETIC LOWER EXTREMITY COMPLICATIONS REQUIRING HOSPITALIZATION IN SEVEN COUNTIES OF PA 2010-2016	33
24.	INDOCYANINE GREEN ANGIOGRAPHY FOR THE ASSESSMENT OF ISCHEMIC WOUNDS: A GAME CHANGER IN LIMB PRESERVATION	34
25.	HIGH BACTERIAL ROAD IMPAIRS CELL PROLIFERATION IN THE GRANULATION TISSUE OF PRESSURE ULCERS	36
26.	COMPREHENSIVE INTERPROFESSIONAL ASSESSMENTS IMPROVED WOUND RELATED DIAGNOSES AND HEALING TRAJECTORY FOR HOME CARE PATIENTS WITH STALLED COMPLEX CHRONIC WOUNDS	38
27.	CHRONIC COMPLEX LEG ULCER RETROSPECTIVE REVIEW WITH A COMPREHENSIVE INTERPROFESSIONAL ASSESSMENT RESULTING IN IMPROVED WOUND HEALING TRAJECTORY	39
28.	ACOUSTIC PRESSURE SHOCKWAVES: A NOVEL ADVANCED THERAPY FOR WOUND MANAGEMENT	40
29.	REGENERATION OF FULL THICKNESS HAIR-BEARING SKIN IN CHRONIC REFRACTORY WOUNDS WITH AN AUTOLOGOUS HOMOLOGOUS SKIN CONSTRUCT: PRECLINICAL AND CLINICAL EXPERIENCE	42
30.	PREDNISONE EFFECTS ON POST-LATERAL MALLEOLAR FRACTURE OPEN WOUND, LIMB SALVAGE AND WOUND HEALING	43
31.	ACELLULAR FISH SKIN PREVENTS RE-INFECTION AND AMPUTATION IN EXPOSED BONE LOWER EXTREMITY WOUNDS WITH HISTORY OF MRSA AND CHRONIC OSTEOMYELITIS	44

ORAL ABSTRACT PRESENTATIONS

Saturday, September 8, 2018
7:00 am – 7:45 am
Holiday Ballroom 1-3
Moderator: Julio E. Garcia, RN, MD, AAPWCA

7:00 AM
CAN NEAR INFRARED SPECTROSCOPY (NIRS) REPLACE TRANSCUTANEOUS OXIMETRY IN THE CLINICAL MANAGEMENT OF COMPROMISED WOUND?

Authors: Brandon C. Hoffman, BS; Jonathan A. Niezgoda, MA; Ross L. Rybakowicz, BS; Jeffrey A. Niezgoda, MD, FACHM, MAPWCA, CHWS

Presenter: Brandon C. Hoffman, BS
Advancing the Zenith of Healthcare Wound & Vascular Center
Milwaukee, WI

7:06 AM
NOVEL UTILIZATION OF NEAR INFRARED SPECTROSCOPY (NIRS) IMAGING IN DEMONSTRATING THE CLINICAL EFFICACY OF ARTERIAL ENDOVASCULAR INTERVENTION

Authors: Jonathan A. Niezgoda, MA; Brandon C. Hoffman, BS; Ross L. Rybakowicz, BS; Awais Siddique, MD; Jeffrey A. Niezgoda, MD, FACHM, MAPWCA, CHWS

Presenter: Jonathan A. Niezgoda, CNA
Advancing the Zenith of Healthcare Wound & Vascular Center
Milwaukee, WI

7:12 AM
THE INCIDENCE OF DIABETIC LOWER EXTREMITY COMPLICATIONS REQUIRING HOSPITALIZATION IN SEVEN COUNTIES OF PA 2010-2016

Authors: Ronald M. Renzi, DPM; Deep Shah, BS; Rebecca Van Dyke, BS; Farhad Foroudi, DPM

Presenter: Ronald M. Renzi, DPM
Abington Hospital/Jefferson Health
Abington, PA

7:18 AM
A NOVEL APPROACH TO NEGATIVE PRESSURE WOUND THERAPY- USE OF A HIGH SUCTION CAPILLARY DRESSING TO IMPROVE WOUND HEALING

Authors: Ranjit Chatterjee, PhD; G. F. Babcock, PhD; T.M. Riddle BS; M. K. Poskarbiewicz RVT

Presenter: Ranjit Chatterjee, PhD
Dristi LLC
Cincinnati, Ohio USA

7:24 AM
REGENERATION OF FULL THICKNESS HAIR-BEARING SKIN IN CHRONIC REFRACTORY WOUNDS WITH AN AUTOLOGOUS HOMOLOGOUS SKIN CONSTRUCT: PRECLINICAL AND CLINICAL EXPERIENCE

Authors: Nikolai Sopko, MD, PhD; Naveen Krishnan; Georgia Yalanis; Devin Miller; Nick Baetz; Ryan Mathis; Pratima Labroo; Caroline Garrett; Edward Swanson; Maurice Nahabedian; Stephen Milner; Mark Granick

Presenter: Nikolai Sopko, MD, PhD
PolarityTE, Inc.
Salt Lake City, UT, USA

7:30 AM
DOUBLE-BLIND, PROSPECTIVE, RANDOMIZED CLINICAL TRIAL ON 170 ACUTE WOUNDS SHOWS SIGNIFICANTLY FASTER HEALING RATE WITH INTACT FISH SKIN COMPARED TO HUMAN AMNIOTIC MEMBRANE

Authors: John C. Lantis II MD, FACS; Kristin Petursdottir, MD; Baldur Baldursson; Robert S. Kirsner, MD, PHD, FAAD; Dot Weir, RN, CWON, CWS

Presenter: John C. Lantis II MD, FACS
Mount Sinai St. Luke's and West Hospitals
New York, NY

7:36 AM
HIGH BACTERIAL ROAD IMPAIRS CELL PROLIFERATION IN THE GRANULATION TISSUE OF PRESSURE ULCERS

Authors: Tomoya Sato, MD; Takahiro Abe, MD, PhD, Shigeru Ichioka, MD, PhD

Presenter: Tomoya Sato, MD
Department of Plastic and Reconstructive Surgery, Saitama Medical University
Saitama, Japan

7:42 AM
QUESTIONS AND ANSWERS

7:45 AM
BREAK

ABSTRACT 1

OMEGA-3 RICH FISH SKIN FOR HEALING OF CHRONIC WOUNDS IN THE PRIVATE OFFICE

Author(s): Bert Altmanshofer, DPM[1]

Background: Achieving optimal healing outcomes in diabetic foot ulcers in the private office is a combination of patient motivation for compliance, achieving optimal biomechanical offloading and management of treatable underlying causes.

Offloading devices can be burdensome to patients and the longer they have to wear one the compliance decreases.

Achieving healing within the window of maximum compliance can make the difference between a fully healed wound and long term chronicity.
Omega3 rich Acellular Fish Skin* has been shown to increase speed of healing in wounds. The aim of this study was to explore the advantages of using the fish skin in a Private Office setting for chronic diabetic foot ulcers

Methods: 12 consecutive diabetic foot ulcers treated at a single private office in PA were treated with acellular fish skin in combination with offloading devices.

Results: Compliance with the treatment regimen of weekly fish skin application and offloading devices remained high during the treatment period. All wounds were brought to full closure.

Conclusion: In the private office having treatment options that are safe, shelf stable and easy to use for the physician and patient provide opportunities for high compliance and increased value for the doctor patient relationship.

Trademarked Items:
* Kerecis™ Omega3 by Kerecis

ABSTRACT 2

MULTISPECTRAL OXYGENATION IMAGING ASSISTED WOUND DEBRIDEMENT - DIRECTING THOROUGH DEBRIDEMENT AND PREDICTING EFFICACY OF CELLULAR TISSUE PRODUCTS

Author(s): Barbara Aung, DPM[1]

Affiliation(s): Aung Foot Health Clinic, Tucson, AZ, USA[1]

Background: Kent Imaging's KD203
A basic tenet of wound management is that of Debridement. It is considered a standard of care, after confirming or correlating that there is adequate blood flow; to remove necrotic or non-viable tissues. Thorough wound bed preparation is a method of returning a chronic, inactive or non-progressing wound to that equivalent state of an acute wound - where there is a balanced wound environment; in which it is free of bioburden and controlled inflammatory factors that when not balanced may lead to a "stalled wound or better known as a chronic wound".

Methods: Using the Multispectral Imaging Device this clinician was able to determine immediately at chair side - oxygenation level in the wound bed - or just under the non-viable tissue, and then using the image to guide full thickness sharp debridement to remove non-viable tissue with greater assurance that the necrotic or non-viable tissue was completely removed from the wound bed. Using repeated imaging during the debridement to help direct the clinician to allow removal of what appears on the image as all of the non-viable tissue. Immediate post debridement recalculation of tissue oxygenation level at the wound bed is also performed to assess if there is increasing oxygenation level at sites where the necrotic tissues are removed.

Results: Immediate significant improvement in the wound bed was visible by increased "red/orange" spectrum on the image obtained and the progression of the wound is followed to evaluate healing with the use of the non-ionizing, non-invasive Multispectral Imaging device with relative ease of use by the clinician and or staff members.

Conclusion: This novel technology may provide potential cost savings to the healthcare system - when used to monitor removal of necrotic tissue and tissue oxygenation levels at wound bed - which may indicate that the wound bed is now ready for more advanced wound care modalities. Advanced therapies such as 'skin substitutes', Cellular Tissue Products are costly and can often be over utilized or applied at inappropriate times as clinicians do not have a method to indicate that the wound bed is appropriately prepared for these tissues; other than visual inspection.

This modality may provide a more scientific method to assess thoroughness of wound debridement and tissue oxygenation levels can be determined more quickly and with less operator error than current modalities such as TcPO2. This technology may lend itself to predict the outcomes when using these costly modalities in a more efficacious manner. We may be able to predict when the wound bed is best suited to accept these tissue substitutes or that the wound bed is not at a state to allow the Cellular Therapy Products to achieve the outcomes desired.

References:
Correlation of Near Infrared Spectroscopy Measurements of Tissue Oxygen Saturation with Transcutaneous pO2 in Patients with Chronic Wounds
Robert E. Bowen, M.D., Ginna Treadwell RN, and Mark Goodwin RRT
SM Vascular Medicine

Predicting Wound Closure and Flap Viability Using Near Infrared Spectroscopy (NIRS)Adam Landsman, DPM, PhD, Harvard Medical School, Boston, MA and Darrell Barnhart, BSEE, Kent Imaging, Inc., Calgary AB, Canada

ABSTRACT 3

PINCH GRAFTING

Author(s): Dr. Baldur T. Baldursson PhD[1]

Introduction: Although office pinch grafting is not used very frequently today, it is still a feasible technique that has a role in managing small burns, neuroischemic and stasis ulcers. These small, full-thickness grafts have a reputation for not being as cosmetically appealing as split-thickness or synthetic-tissue grafts as they can leave a cobblestone appearance at both the donor and the recipient site. However, they are effective and can be performed in any setting. The technique for pinch grafts has not changed over the years but in this case series we show that the use of pinch grafts can have accelerated healing and visually acceptable outcomes. Furthermore, the combination of pinch grafts with modern skin substitutes can be used together to prepare the wound bed and improve visual outcomes.

Methods: Retrospective study of wounds treated at a single site in the University Hospital in Iceland. Cases collected from January 2014 – December 2017. Pinch grafting was done in the outpatient wound care clinic under local anesthesia. Patients were followed up until full closure. Some wounds received acellular fish skin to prepare the wound bed for improved graft take or had fish skin placed on top of the pinch graft to salvage failing grafts. Patients furthermore received standard debridement and wound cleaning and compression therapy per institutional guidelines.

Results: 10 patients with venous leg ulcers treated with pinch grafts. 8 patients had achieved full healing within 12 weeks. 2 patients had early signs of graft failure but responded to a salvaging covering with an acellular fish skin graft and went on to full healing.

Conclusion: Pinch grafting can be used successfully to treat chronic treatment resistant wounds in the office setting. Compared to split skin grafting it allows for an inexpensive and quick wound area reduction that can have a high take rate because of selective grafting of the healthiest areas of the wound. It can be used in combination with skin substitutes in larger wounds where closure with secondary intention alone would be too time consuming.

Keywords:
Pinch grafting, venous leg ulcer, neuroischemic ulcer, fish skin

Reference:

1. Fox, J. D. *et al.* Optimizing Skin Grafting Using Hair-derived Skin Grafts: The Healing Potential of Hair Follicle Pluripotent Stem Cells. *Wounds* **28,** 109–111 (2016).

2. Ramanujam, C. L. & Zgonis, T. Pinch Graft Harvesting Technique for Surgical Closure of the Diabetic Foot. *Clinics in Podiatric Medicine and Surgery* **29,** 585–588 (2012).

3. Hjerppe, A., Sane, M., Huhtala, H. & Vaalasti, A. Pinch grafting of chronic leg ulcers: a retrospective analysis of 104 patients with 169 ulcers. *Journal of Wound Care* **19,** 37–40 (2010).

4. F. Öien, Bjarne U. Hansen, R. Pinch Grafting of Leg Ulcers in Primary Care. *Acta Dermato-Venereologica* **78,** 438–439 (1998).

5. Wheeland, R. G. The technique and current status of pinch grafting. *J Dermatol Surg Oncol* **13,** 873–880 (1987).

ABSTRACT 4

HEALTH CARE EXPERIENCES OF A CHRONIC WOUND PATIENT: FACTORS THAT MAY PROMOTE AND HINDER WOUND HEALING

Author(s): Alisa Brandon[1,2], James A. Elliott[2], Patricia Coutts[2], R. Gary Sibbald[1,2,3]

Affiliation(s): University of Toronto, Toronto, Ontario, Canada[1]
Toronto Regional Wound Healing Clinic, Toronto, Ontario, Canada[2]
International Interprofessional Wound Care Course, Toronto, Ontario, Canada[3]

Background: Research has shown that the health care systems often struggle to meet the needs of patients with chronic wounds. These patients often spend prolonged periods with the wrong diagnosis and inadequate care before being referred to wound care centres or specialists. The few qualitative studies that have focused on patients with chronic wounds are out-dated and, to our knowledge, none have been based in Canada. It is necessary to document the challenges and positives that patients with chronic wounds experience to inform health system reform.

Methods: We conducted a 45-minute semi-structured patient interview with a person living with a chronic wound from the interprofessional Toronto Regional Wound Healing Clinic (TRWHC) located in Mississauga, Ontario, Canada. This research is part of a larger qualitative study on the experiences of chronic wound patients residing in southern Ontario within the health care system.

Results: A woman in her 70s living with a re-occurring chronic leg ulcer for 14 years was interviewed. Analysis revealed several health system factors that may have affected wound healing including: lack of timely referral to appropriate services, lack of adequate time and training among home care nurses, and inappropriate provision and use of wound supplies. A positive factor was home care management being attentive to her concerns and attempting to make necessary changes.

Prior to being referred to the TRWHC, she received multiple referrals to various specialists (cosmetic dermatologist, clinical dermatologist, vascular surgeon) who had limited chronic wound knowledge. After 5 years of visiting various specialists with limited improvement in the size of her wound, an acquaintance employed as a registered nurse (RN) recommended the TRWHC. Under the TRWHC, the patient's wound closed for the first time.

Home care is often provided by RNs and RPNs with inadequate clinical hands on training and time allocated to individual care. The patient reported having to demonstrate to multiple RNs compression wrapping techniques. Furthermore, 14 years ago she would receive all aspects of local wound care from home care nurses. She must now unwrap and wash her own wound in preparation for debridement and re-wrapping by the RNs.

The patient's healing was further hindered because she was not consistently receiving the wound care products she needed in a timely fashion. For example, wound size was decreasing with the use of a wearable medical device (battery operated electrical stimulation device attached to the calf muscle); unfortunately, the device was taken away because home care would only fund it for a specific number of weeks per patient (4-6 weeks). On the other hand, the patient was being given wound products she had no need for and did not request. These products were picked up for disposal once delivered.

Conclusion: This patient's experience exemplifies how publicly funded health care systems may fail to provide the optimal environment for wound healing due to lack of chronic wound training for health care providers, insufficient funding for home care employees, and poor health system organization. However, home care management was receptive to the patient's needs and attempted to make changes requested by patient.

ABSTRACT 5

CHARACTERISTICS, MANAGEMENT, AND OUTCOMES OF PATIENTS WITH SURGICAL WOUNDS REFERRED TO AN INTERPROFESSIONAL WOUND CARE TEAM: A RETROSPECTIVE COHORT STUDY

Author(s): Alisa Brandon[1,2], James A. Elliott[2], Reneeka Persaud-Jaimangal[2], Asfandayer Mufti[1], Ranjani Somayaji[3], Morgan Lim[1], Laurie Goodman[2,4], R. Gary Sibbald[1,2,4]

Affiliation(s): University of Toronto, Toronto, Ontario, Canada[1]
Toronto Regional Wound Healing Clinic, Toronto, Ontario, Canada[2]
University of Calgary, Calgary, Alberta, Canada[3]
International Interprofessional Wound Care Course, Toronto, Ontario, Canada[4]

Background: Post-surgical wound are frequent and costly complications. Clinicians who do not have extensive wound care training or experience may find it difficult to effectively treat post-surgical wounds. The study documented diagnosis and treatment plans for patients living with stalled post-surgical wounds in order to evaluate the results of a comprehensive interprofessional assessment.

Methods: This retrospective cohort study was based on patients referred by the local Home Care administrative team to an interprofessional wound care team. Inclusion criteria included referral between February 11, 2013 and September 30, 2014 for a surgical wound. Information on patient demographics, comorbidities, wound parameters, management strategies, and outcomes was collected. Data was analyzed with SPSS (IBM Corp., Armonk, N.Y., USA).

Results: A total of n=24 patients were included for comprehensive wound care team assessment. The median age was 59 (IQR=47.5-63.5) and median BMI was 28.6 (26.9-36.7). Comorbidities included smoking (n=5, 21%), diabetes mellitus (n=5, 21%), malignancy (n=5, 21%), and peripheral vascular disease (n=4, 17%). The most common location was the abdomen (n=15, 63%) and the most common surgical procedure was bowel resection (n=5, 21%). Wounds were heterogeneous in size (median=3.6 cm^2, IQR=0.4-16.5cm^2), and had been present for a mean of 13 weeks (SD=7.54). The home care team correctly recorded 8 wounds as 'post-surgical' (33%), with the rest recorded as 'unknown' etiology (67%).

The home care team performed suboptimally on documentation of healability classifications (n=11 documented, 46%), wound measurements (n=11, 46%), pain assessments (n=0, 0%), and nutritional assessments (n=3, 13%). These parameters were recorded for all patients (n=24, 100%) with the interprofessional team assessment. The home care team diagnosed 3 patients (13%) with infection, no patients with critical colonization, and 7 patients (29%) with "undifferentiated bacterial damage". The interprofessional team diagnosed 14 patients as having critical colonization and 16 as having deep or surrounding tissue infection. Assessment by an interprofessional team was associated with decreased number of dressing changes per week (from 3.5 to 3 changes/week; p=0.14) and decreased pain scores (from 2/10 to 0/10; p=0.06). By week 4, 16 (67%) out of the original 24 patients were still being seen by the interprofessional team. Among this smaller group, 10 (63%) had achieved at least a 30% reduction in wound size. Thirteen patients continued being managed by the interprofessional team past 4 weeks. By their final visit (median 6 weeks), 4 of these patients (31%) had achieved complete wound closure.

Conclusion: Diagnosis, secondary diagnosis, and coexisting disease achieved enhanced categorization through an interprofessional environment. Furthermore, an interprofessional environment resulted in improved healing rates for stalled-post surgical wounds.

ABSTRACT 6

A NOVEL APPROACH TO NEGATIVE PRESSURE WOUND THERAPY- USE OF A HIGH SUCTION CAPILLARY DRESSING TO IMPROVE WOUND HEALING

Author(s): R. Chatterjee, PhD[1], G. F. Babcock, PhD[2,3], T.M. Riddle BS[2], M. K. Poskarbiewicz RVT[2]

Affiliation(s): Dristi LLC, Cincinnati, Ohio USA [1]
Dept of Surgery, University of Cincinnati, Ohio, USA [2]
Shriners- Hospitals for Children, Cincinnati, Ohio, USA [3]

Background: Vacuum assisted negative pressure wound therapy (VA-NPWT) has been a useful therapeutic procedure for non-healing wounds and for acute burn wounds. The benefit of VA-NPWT is offset by the burden of using an external pump, increased labor and the associated cost. The goal of developing a Capillary Suction Dressing (CSD) is to provide benefits of VA-NPWT without the negatives of cost and hazards of hospital stay.

Methods: CSD is constructed with polymeric foams made from High Internal Phase Emulsion (HIPE). Several CSD dressings were made with varying cell sizes and gradient configurations to create moderate (~30mm Hg) to high (~50mm Hg) capillary suction. These products were tested for plasma absorption and equilibrium composition at various layers of the dressings. A moderate suction (~30mm Hg) CSD was tested in a rat model with bilateral surgical wounds. The surgical wounds were uninfected or infected with Methicillin-resistant Staphylococcus Aureus (MARSA).

Results: HIPE foam dressings exert high capillary suction pressure at the wound site due to micron size capillaries. A multilayered foam dressing with a gradient of cell sizes between 2 to 130 μm allows effective removal of exudates and maintains a controlled level of moisture in a healing wound.

A mathematical model is presented on the moisture content of the face layer of dressing in contact with wound and the net capillary suction pressure of dressing. Higher suction resulted in a dryer environment. An unusual utility of CSD was observed in the laboratory for its prolonged use without leakage compared with other foam dressings in a constant infusion protocol. The utility was due to constant evaporation of moisture from the back layer and corresponding reduction in dressing load.

Relative to gauze and a conventional foam dressing, CSD delivered significant ($p>0.05$) wound closure in un-infected and infected (MARSA) wounds. The healing benefit in infected wound could not be co-related to bioburden reduction.

Conclusion: CSD dressing can exert high suction pressure due to micro capillaries from the 2 to 15 μm open cells present in HIPE foams. A combined effect of high capillary suction and a gradient of increasing capillary suction away from the healing tissue parallels the aspiration and mechanical stimulation effects of VA- NPWT. Laboratory studies with plasma and blood absorption confirm that dryness and negative pressure are directly controlled by foam cell sizes and gradient in the dressing. These attributes suggest CSD is expected to deliver clinical benefits for complex wounds. To date, we have demonstrated healing of surgical incisional wounds in a rat model. CSD was significantly better in wound closure to conventional gauze and absorbent foam dressings with low capillary suction.

Future animal studies are planned in a pig model to compare VA-NPWT and CSD dressings with moderate and high suction pressures. The purpose of these studies is to determine healing stimulation by negative capillary pressure compared to the low range of pump-mediated suction pressure typically used in VA-NPWT. The clinical implication of the outcome of the pig study would be to reduce or obviate the need for VA-NPWT with the use of CSD.

ABSTRACT 7

WHEN HEALING IS NOT THE GOAL

Author(s): Ingrid Franco, BS, RN, CWCN, OMS[1], Connie Johnson, MSN, RN, WCC, OMS, LLE, DWC[2]

Affiliation(s): PENN at Princeton Medical Center, Plainsboro, NJ, USA[1]

Background: As wound care nurses, we want to heal wounds. But there are some cases where healing is not the goal, such as in fungating wounds. Our goal is to improve quality of life by managing drainage, odor, and pain.

Methods: Utilizing interdisciplinary approach with pain management, oncology, and physical therapy. Wound care included: lidocaine topical gel 2%, metronidazole gel, active *Leptospermum* honey as well as a large double-sided silicone contact layer (reduces adherence of dressings to wound while allowing dressing to adhere to contact layer), rolled gauze, large absorbent dressing, stretchable abdominal binder (securement). And a walk in the garden.

Results: As in the case of a 49-year-old female with recurrent aggressive metastatic high grade Phyllodes tumor and sadly, poor prognosis. Wound and pain management were no longer doable at home, so she came to us for relief. Her wound treatments were daily and could take up to two hours depending on the level of pain but improved with time. Her avulsed tumor, encasing the entire right chest approximately 25cm x 40cm extended through right axilla to upper arm, and some points of elevation were over 4 cm. We also realized at this time that this was not something nursing staff was prepared for. With her first dressing change with items mentioned above, she stated “thank you, I don’t smell anymore.” Unfortunately, this patient is no longer with us but her smile, strength and courage remain with us today. When she passed, we helped her family prepare her body to be taken home for a cultural service including her last dressing change, we washed and dressed her.

Conclusion: Through an interdisciplinary approach as well as with multiple topical treatments, we were able to improve this patient’s quality of life during her last days by managing pain, odor, and exudate.

References:

1. Alvarez, OM et al. (2007). Incorporating wound healing strategies to improve palliation (symptom management) in patients with chronic wounds. *J Palliat Med 10*(5), 1161-1189.

2. Bryant, R. A., & Nix, D. P. (2012). Acute & Chronic Wounds: Current Management Concepts (4th ed.). St. Louis, MO: Elsevier.

3. Segovia, D. (2010). The Clinical Benefits of Active Leptospermum Honey in Oncologic Wounds. *Ostomy Wound Management 56*(10). Retrieved from https://www.o-wm.com/content/clinical-benefits-active-leptospermum-honey-oncologic-wounds

ABSTRACT 8

ONE SIZE DOES NOT FIT ALL

Author(s): I. Franco, BS, RN, CWCN, OMS, C. Johnson, MSN, RN, WCC, LLE, OMS, DWC, J. Kelly, BSN, RN, CWOCN

Affiliation(s): PENN at Princeton Medical Center, Plainsboro, NJ, USA[1]

Background: To raise awareness that a stoma is not always as pretty as a rose bud; this may make effluent difficult to manage. Ostomy nurses need to be readily available, possess knowledge, compassion and supplies.

Methods: Patient #1--32 yo male with history of ulcerative colitis, loop ileostomy shown, patient has had temporary colostomy in past. Able to manage independently. Patient #2--42 yo female, recent bowel resection secondary to cancer; 4 weeks post-op bowel obstruction due to extensive adhesions; temporary ileostomy, mucocutaneous separation from 11-3 secondary to fistula behind stoma; reversed at 5 weeks post-op due to difficulty managing appliance. #3—54 yo female, permanent colostomy secondary to extensive history of Crohn's disease; difficult to find appropriate appliance, patient was custom molded, manages well on own. #4--84 yo female, ileostomy secondary to obstruction; patient did not remain stable in surgery, surgeon was rushed to get patient off table; retracted stoma LLQ, 10 days of trial and error, convex precut with good results patient was transferred to sub-acute rehab and returned 8 days later as they ran out of barriers and could not get a good fit with what they had on hand. Peristomal excoriation secondary to effluent on abdomen persisted.

Results: Each patient in each case is so different that management of effluent, peristomal skin and emotions need to be addressed individually. Any surgery can be debilitating; ostomy surgery is a major life changing surgery. In an emergent situation it is not possible to appropriately mark patients, so appliance fitting may be difficult.

Conclusion: In the ideal world post-op ostomy patients should be fitted for appliance and sent on their way to manage their major life changing event successfully. In reality, as an ostomy nurse, you become part of the patient's family.

References:

1. Ostomy Management Course, 2013. *Skin and Wound Course Management Workbook*, Wound Care Education Institute, Lake Geneva, WI.

2. United Ostomy Association of America (UOAA), 2011. *What is an ostomy?,* Retrieved from: UOAA.org.

3. Coloplast, Inc., 2009. *The Ostomy Tool Kit,* Retrieved from: Coloplast.com.

ABSTRACT 9

APPLICATION OF CONTINUOUS EXTERNAL TISSUE EXPANDER (DERMACLOSE) FOR DELAYED CLOSURE OF LOWER EXTREMITY WOUND FOLLOWING COMPARTMENT SYNDROME FASCIOTOMY: A CASE REPORT

Author(s): Gan Golshteyn, MS, DPM,[1] Mashail Manzur, DPM,[1] Alton Johnson, DPM,[1] Marie Williams, DPM, FACFAS[2], Jean Holewinski, DPM[3]

Affiliation(s): Podiatric Surgical Resident, Aventura Hospital and Medical Center, Aventura, FL, USA[1]
Residency Program Director, Aventura Hospital and Medical Center, Aventura, FL, USA[2]
Resident Program Clinical Director, Aventura Hospital and Medical Center, Aventura, FL, USA[3]

The purpose of this case study is to investigate the post-operative outcome following the application of continuous external tissue expander (DermaClose™) without the use of a negative pressure wound vac in a patient that sustained a gunshot wound to the left lower abdominal quadrant and suprapubic area. Patient presented to Aventura Hospital Medical Center Emergency Department, trauma bay, GCS 14 with palpable pulses of the left lower extremity and non-palpable femoral, popliteal, dorsalis pedis (DP), and posterior tibialis (PT) pulses of the right lower extremity. Patient was called stage IV hemorrhagic shock with greater than 20% blood loss, advanced imaging noted with common femoral artery (CFA) laceration, right profunda femoris laceration, and right saphenous vein (SV) laceration. Patient was re-vascularized emergently with results of dopplerable and palpable DP and PT. He then went on to develop post-operative compartment syndrome of the right lower extremity and underwent emergent medial and lateral fasciotomies, multiple irrigation and application of negative pressure wound vac by the trauma team in effort to salvage the limb. The next consideration for the patient was going to be a below the knee amputation. Our team was consulted for further right lower extremity limb salvage and delayed closure of right lower extremity fasciotomy sites, measuring 10cm x 40cm on the medial aspect and 14cm x 40cm on the lateral aspect, down to level of muscle and tendon. Application of continuous external tissue expander (DermaClose™) was applied to both medial and lateral fasciotomy sites of the right lower extremity, which utilizes multiple steel clips held by anchors that allows for continuous pressure for adequate delayed closure and reduces the use of skin grafting with an average closure of 9,6 days in comparison to 36.4 days using traditional methods. In this case study, our patient achieved complete closure of the medial fasciotomy site at day 20 and 73% advanced closure of the lateral aspect with healthy granular wound bed and smooth edges.

DermaClose™ is a registered trademark of Wound Care Technologies Inc. Chanhassen, MN

ABSTRACT 10

BLOOD FLOW REALLY DOES MATTER

Author(s): H. David Gottlieb DPM, DABPM, FAPWCA; John Miller DPM, PGY-2

Affiliation(s): Baltimore VA, VAMHCS

Category: Case Presentation

Background: 69 year old diabetic male with non healing pedal wound following hallux amputation seen in clinic. Patient refused attempts at revascularization, and continued with a nonhealing wound for 17 months. Following eventual revascularization wound is able to be healed in under 2 months time without complication.

Methods: Retrospective case review of both clinical and photographic data.

Results: Following revascularization, chronic wound is healed.

Conclusion: Revascularization is critical for healing avascular tissue in diabetic patients.

ABSTRACT 11

SURGICAL OFF-LOADING HEALS DIABETIC WOUNDS

Author(s): H. David Gottlieb DPM, DABPM, FAPWCA; John Miller DPM, PGY-2

Affiliation(s): Baltimore VA, VAMHCS

Category: Case Presentation

Background: 68 year old diabetic male with non healing wound seen in clinic. Patient refused operative management. Following 3 years of attempted conservative treatment modalities, patient consented to surgical treatment. Following osseous resection of offending exostosis, chronic wound was healed in 2 weeks.

Methods: Retrospective case review of both clinical and photographic data.

Results: Successful wound healing at 2 weeks following surgical resection offending exostosis.

Conclusion: Surgical offloading is valuable but oftentimes overlooked technique for resolving chronic diabetic wounds.

ABSTRACT 12

AGGRESSIVE CONSERVATIVE WOUND CARE: HEAL WOUNDS, PREVENT AMPUTATION

Author(s): H. David Gottlieb DPM, DABPM, FAPWCA; John Miller DPM, PGY-2

Affiliation(s): Baltimore VA, VAMHCS

Category: Case Presentation

Background: Aggressive Conservative Wound Care (ACWC) is a series of five principles constructed from evidence-based medicine to elicit the best possible wound healing outcomes when surgical modalities may not be possible.

Methods: Retrospective case review of both clinical and photographic data.

Results: This case presentation demonstrates the application and effectiveness of ACWC when applied to a patient without surgical options.

Conclusion: Effective use of Aggressive Conservative Wound Care principles is a powerful option for wound healing without the need for surgical intervention.

ABSTRACT 13

COST EFFECTIVENESS OF WOUND TREATMENT WITH FISH SKIN - RESULTS OF A PROGNOSTIC STUDY

Author(s): Hulda S. Jonasdottir PhD[1], Rosa S. Sigurdardottir BSc,[1] Ingibjorg L. Haflidadottir BSc,[1] Skuli Magnusson BSc,[2] Gunnar Johannsson MD,[2,3] Hilmar Kjartansson MD FACS,[2,3] Baldur T. Baldursson MD PhD,[2,3] Ottar Rolfsson PhD,[1] John C. Lantis II MD FACS,[4] G. Fertram Sigurjonsson MEng,[2]

Affiliation(s): Center for Systems Biology, University of Iceland, Reykjavik, Iceland[1]
Kerecis, Reykjavik, Iceland[2]
Landspitali - University Hospital of Iceland, Reykjavik, Iceland[3]
Mount Sinai Hospital, NY, USA[4]

Background: The use of prognostic and cost models gives healthcare providers a relatively quick and easy opportunity to estimate when it will be cost efficient to use advanced treatment such as biologic skin substitutes.

In this cost simulation study the Margolis prognostic model for DFUs[1] was used to evaluate the potential cost benefit of using acellular fish skin* for hard to heal wounds.

Methods: Retrospective collection of data from 27 DFUs treated with acellular fish skin* at a single center which was inserted into a prognostic model, and compared with the actual outcome of the treatment.

This delta between the two groups was then multiplied against a standardized cost model which includes; the cost of product, the cost of application, and weekly versus daily standard of care dressing and nursing costs.

Results: These 27 patients had had hard to heal wounds with an average age of 16 weeks, Wagner grade 2,03 and wound size of 4.58cm^2. The prognostic model predicted that only 42% would close after 20 weeks with standard of care. Using an average of 5,6 applications of fish skin, those wounds took on average 8,7 weeks to close with 89% closing.

The fish skin treatment resulted in 2.18x more healed wounds than predicted at 20 weeks. This resulted in a 62.5% total cost reduction for those patients that healed despite the added cost of the skin substitute for an average savings of $3018 per wound treated.

Conclusion: This study shows that over a 20 week treatment period the use of fish skin for hard to heal DFUs can lead to improved outcomes and cost savings for healthcare providers. Further studies could demonstrate if the use of fish skin is cost beneficial for more wound types and less severe wounds.

Trademarked Items:
* Kerecis™ Omega3 by Kerecis

References:
1. Margolis, D. J., Allen-Taylor, L., Hoffstad, O. & Berlin, J. A. Diabetic neuropathic foot ulcers: predicting which ones will not heal. Am. J. Med. 115, 627–631 (2003).

ABSTRACT 14

FISH SKIN GRAFTS-OMEGA3 FATTY ACIDS ARE A SOURCE FOR THE SPECIALIZED PRO-RESOLVING MEDIATORS THAT DRIVE INFLAMMATION RESOLUTION

Author(s): Hulda S. Jonasdottir PhD[1], Rosa S. Sigurdardottir BSc,[1] Ingibjorg L. Haflidadottir BSc,[1] Skuli Magnusson BSc,[2] Gunnar Johannsson MD,[2,3] Hilmar Kjartansson MD FACS,[2,3] Baldur T. Baldursson MD PhD,[2,3] Ottar Rolfsson PhD,[1] John C. Lantis II MD FACS,[4] G. Fertram Sigurjonsson MEng,[2]

Affiliation(s): Center for Systems Biology, University of Iceland, Reykjavik, Iceland[1]
Kerecis, Reykjavik, Iceland[2]
Landspitali - University Hospital of Iceland, Reykjavik, Iceland[3]
Mount Sinai Hospital, NY, USA[4]

Background: Most cellular and tissue based products (CTPs) are derived from livestock or human amniotic membranes and require heavy processing due to disease transmission risk. This removes bioactive components and denatures microstructure, leaving behind only a matrix of the most insoluble collagens.[1,2]

Fish skin grafts* CTPs undergo gentler processing methods since they (*Gadus morhua*) do not pose a disease transmission risk to humans,[3] preserving bioactive components and skin-for-skin microstructure.[4,5]

Fish skin grafts* are rich in omega-3 EPA and DHA fatty acids, necessary for biosynthesis of the specialized pro-resolving lipid mediators (SPMs) that orchestrate inflammation resolution and are lacking in chronic wounds.[6,7]

Aim: 1) To compare the lipid content and profile in fish skin grafts* with human skin and amnion membrane# and collagen matrix CTP. 2) Study the effects of fish skin* lipids on HaCat migration SPMs pathways.

Methods: Lipids were extracted using liquid-liquid extraction. Fatty acid analysis was done with gas chromatography and lipid analysis with liquid chromatography-mass spectrometry.
Wound healing assay was done with the Culture Insert 2 well (Ibidi GmbH) and carried out using HaCaT keratinocytes (ATCC® PCS-200-010™). The qPCR was done with PrimeTime® Assay Kit.

Results: Fish skin grafts contain >30 times higher ratio of Omega-3/total fatty acids and distinctively different lipid profile compared to the other CTPs. Fish skin lipids induce the migration of HaCat keratinocytes and the transcription of ALOX-15 SPMs forming lioxygenase.

Conclusion: Conclusion: Clinical evidence for the use of fish skin grafts is growing and has shown faster healing in a comparative RCT,[3] chronic wounds,[8,9] reduction in bacterial infiltration[4] and pain.[9]

The results here along with other pre-clinical data[4,5] show that the clinical efficacy of the fish skin grafts can be attributed to the unique combination of preserved skin-for-skin microstructure enriched with omega-3 fatty acids.

Trademarked Items:
* Kerecis™ Omega3 Wound by Kerecis
# Epifix® by MiMedx

References:

1. Crapo PM, Gilbert TW, Badylak SF. An overview of tissue and whole organ decellularization processes. Biomaterials. 2011 Apr;32(12):3233–43.

2. Keane TJ, Swinehart IT, Badylak SF. Methods of tissue decellularization used for preparation of biologic scaffolds and in vivo relevance. Methods San Diego Calif. 2015 Aug;84:25–34.

3. Baldursson BT, Kjartansson H, Konradsdottir F, Gudnason P, Sigurjonsson GF, Lund SH. Healing rate and autoimmune safety of full-thickness wounds treated with fish skin acellular dermal matrix versus porcine small-intestine submucosa: a noninferiority study. Int J Low Extrem Wounds. 2015 Mar;14(1).

4. Magnusson S, Baldursson BT, Kjartansson H, Rolfsson O, Sigurjonsson GF. Regenerative and Antibacterial Properties of Acellular Fish Skin Grafts and Human Amnion/Chorion Membrane: Implications for Tissue Preservation in Combat Casualty Care. Mil Med. 2017 Mar;182(S1):383–8.

5. Magnússon S, Baldursson BT, Kjartansson H, Thorlacius GE, Axelsson Í, Rolfsson Ó, et al. [Decellularized fish skin: characteristics that support tissue repair]. Laeknabladid. 2015 Dec;101(12):567–73.

6. Serhan CN. Pro-resolving lipid mediators are leads for resolution physiology. Nature. 2014 Jun 5;510(7503):92–101.

7. Leoni G, Neumann P-A, Sumagin R, Denning TL, Nusrat A. Wound repair: role of immune–epithelial interactions. Mucosal Immunol. 2015 Jul 15;8(5):mi201563.

8. Chun K. Yang, John C. Lantis II, Thais O. Polanco. A prospective, single-center, non-blinded, non-comparative, post-market compassionate clinical evaluation of a Novel Acellular Fish Skin Graft which contains Omega3 fatty acids, for the closure of hard to heal lower extremity chronic ulcers. Wounds. 2016;28(4):112–8.

9. T. T. Trinh, F. Dünschede, C.-F. Vahl, B. Dorweiler. Marine Omega3 Wound Matrix for the Treatment of Complicated Wounds. Phlebologie. 2016;45:93–8.

ABSTRACT 15

DOUBLE-BLIND, PROSPECTIVE, RANDOMIZED CLINICAL TRIAL ON 170 ACUTE WOUNDS SHOWS SIGNIFICANTLY FASTER HEALING RATE WITH INTACT FISH SKIN COMPARED TO HUMAN AMNIOTIC MEMBRANE

Author(s): John C. Lantis II MD, FACS,[1] Kristin Petursdottir, MD,[1] Baldur Baldursson[1] Robert S. Kirsner, MD, PHD, FAAD,[3] Dot Weir, RN, CWON, CWS,[4]

Affiliation(s): Mount Sinai St. Luke's and West Hospitals, NY, USA[1]
Landspitali – University Hospital of Iceland[2]
Department of Dermatology & Cutaneous Surgery University of Miami Miller School of Medicine[3]
The Wound Healing Center of Osceola Region Medical Center Orlando, FL, USA[4]

Background: Fish skin grafts* are skin substitutes containing omega-3 EPA and DHA fatty acids.[1] Amniotic membrane allografts (dHACM)# are used extensively to heal chronic wounds.[2] In this study we compare the efficacy of the fish skin grafts to dHACM in the closure rate of acute wounds. The primary objective was to determine treating acute wounds with fish skin is superior to dHACM.

Methods: A double-blind, prospective, randomized, comparative clinical trial on 170 acute wounds. Each participant had two 4-mm forearm punch wounds created, then one was treated with fish skin, and the other with dHACM. Primary endpoint was time to heal (complete epithelialization) by blinded assessment at days 14, 18, 21, 25 and 28. For statistical analysis a mixed effects Cox-Proportional Hazard using the survival[3] & coxme[4] packages in R version 3.3.1[5] was used. Each time point was assessed with non-parametric bootstrap test.

Results: The fish skin group healed significantly faster with a hazard ratio of 2.37 (95% CI: 1.75-3.22; p=0.0014) (Fig 1). Wound healing was faster in the fish skin group at all time points with 68%, 83%, 50%, 26% and 10% more wounds healed. At individual time points, the time to heal was statistically significant ($p<0.05$) at day 21 and 25.

Conclusion: The results show that fish skin grafts are superior in time to heal on acute wounds compared to dHACM. Earlier in vitro study showed significantly more cell ingrowth in fish skin compared to dHACM[6] suggesting a mechanism of action for faster healing rates.

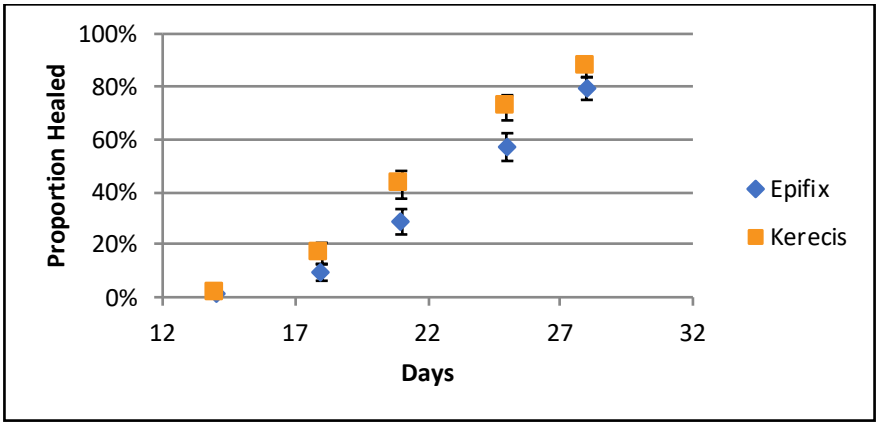

Fig 1: survival curves for each treatment. Fish skin = Orange, dHCAM = blue. Dotted lines are error bars.

References:

1. Baldursson BT, Kjartansson H, Konradsdottir F, Gudnason P, Sigurjonsson GF, Lund SH. Healing rate and autoimmune safety of full-thickness wounds treated with fish skin acellular dermal matrix versus porcine small-intestine submucosa: a noninferiority study. Int J Low Extrem Wounds. 2015 Mar;14(1).

2. Zelen CM, Gould L, Serena TE, Carter MJ, Keller J, Li WW. A prospective, randomised, controlled, multi-centre comparative effectiveness study of healing using dehydrated human amnion/chorion membrane allograft, bioengineered skin substitute or standard of care for treatment of chronic lower extremity diabetic ulcers. Int Wound J. 2015 Dec;12(6):724–32.

3. Therneau TM, Grambsch PM. Modeling Survival Data: Extending the Cox Model [Internet]. New York: Springer-Verlag; 2000 [cited 2018 May 29]. (Statistics for Biology and Health). Available from: //www.springer.com/gp/ book/9780387987842.

4. Therneau TM. coxme: Mixed Effects Cox Models [Internet]. 2018 [cited 2018 May 29]. Available from: https:/ CRAN.R-project.org/package=coxme.

5. Team R. R: A language and environment for statistical computing. 2004; Available from: http://www.R-project.org.

6. Magnusson s, Baldursson BT, Kjartansson H, Rolfsson O, Sigurjonsson GF. Regenerative and antibacterial properties of acellular fish skin grafts and human amnion/chorion membrane: Implications for tissue preservation in combat casualty care. Mil Med. 2017MAR;182(S1):383–8.

ABSTRACT 16

A NEW APPROACH IN THE MANAGEMENT OF CHRONIC DIABETIC FOOT ULCERS: A REPORT ON THE USE OF A COLLAGEN WOUND CONTACT LAYER WITH NEGATIVE PRESSURE WOUND THERAPY

Author(s): Jeffrey D. Lehrman, DPM, FASPS, MAPWCA, CPC[1]

Affiliation(s): Foot and Ankle Specialists of Delaware County, Wynnewood, PA, USA[1]

Background: Diabetes affects 30 million children and adults in the US, equivalent to 1 in 11 of the population, and costs the economy $322 billion annually.

Interventions that can improve healing rates or reduce the size of diabetic ulcers may reduce the incidence of infection, reduce amputation rates, and lower the associated costs to healthcare providers. We report on the novel use of a collagen wound contact layer in conjunction with negative wound pressure therapy to achieve healing in a chronic diabetic foot ulcer.

Methods: A known type I diabetic presented with a chronic foot ulcer of 6 months' duration. Previous treatment modalities included offloading regimes, topical therapies such as clostridial collagenase, PDGF, and 6 applications of human amniotic membrane allograft.

A collagen wound contact layer was applied to the debrided wound bed and a regime of biweekly debridement, and weekly negative pressure therapy and change of contact layer was initiated.

Results: A 73% reduction in wound area was seen at day 35, with complete healing at day 63, and no recurrence at 6 months.

Conclusion: The combination of a collagen wound contact layer and weekly negative pressure wound therapy had a significant beneficial effect on healing in this chronic diabetic foot ulcer. The regime was well tolerated and simple to administer, and offers a valuable opportunity for healing in this patient group.

ABSTRACT 17

THE COST AND EFFICACY OF REGENERATIVE WOUND PRODUCTS

Author(s): Kenny Luong, BA[1], Michael Del Rosso, BA[1], Kaitlyn Testa, BS[1], Jones Thomas, BA[1], Einul Chowdhury, BA[1], Jose Grullon, BS[1], Anthony R. Iorio, DPM, MPH[1]

Affiliation(s): New York College of Podiatric Medicine, New York, NY, USA[1]

Background: The purpose of this study is to evaluate regenerative wound products that are currently available for outpatient use. A systematic literature review was conducted to assess the efficacy of FDA approved or regulated regenerative wound products and to compare them to their cost. Additionally, one case report was conducted to evaluate and present the effectiveness of regenerative wound products.

Methods: Web searches were performed to find all FDA approved or regulated regenerative wound products currently available resulting in 23 products. English language literature searches were then conducted on PubMed for those 23 products. Seven of the products did not result in sufficient research, leaving 16 products to be reviewed. Of the 16 products, 25 papers were found that included relevant information on the cost and efficacy of the regenerative wound products.

Results: From the papers that were reviewed, the two main statistics used to represent the efficacy of each wound product were the number of diabetic foot ulcers (DFUs) that healed within a twelve-week period, and the average time it took for those DFUs to heal. The two statistics used to evaluate cost for each product were the number of applications recommended for the treatment of DFUs and the cost of one application.

Case Report: A patient who presented to the clinic with a diabetic wound that failed to heal with standard of care treatment was treated with a regenerative wound product. Upon conclusion of their treatment, the patient's ulcer was healed without complications in 8 weeks.

Conclusion: There are many different regenerative wound products on the market. Because product costs vary and the number of applications for each product varies, determination of which product is superior cannot be concluded. However, the literature does support the use of regenerative wound products on diabetic foot ulcers that have failed standard of care treatment.

ABSTRACT 18

THE HEALTHY FOOT SCREEN: A PILOT OF NOVEL ASSESSMENT TOOL FOR COMMON CLINICAL FOOT ABNORMALITIES

Author(s): Khalad Maliyar, BSc[1]; Alisa Brandon, BSc[1]; Reneeka Persaud-Jaimangal, MD, MScH[2], James A. Elliot[2]; Dr. R. Gary Sibbald, BSc, MD, M.Ed., D.SC (Hon), FRCPC (Med)(Derm), FAAD, MAPWCA, JM [2,3]

Affiliation(s): University of Toronto, Faculty of Medicine, Toronto, ON, CAN[1]
Toronto Regional Wound Clinic, Mississauga, ON, CAN[2]
University of Toronto, Dalla Lana School of Public Health[3]

Background: There is a need for primary care providers to implement general population routine foot screening protocols. Foot health is fundamental to overall health and well-being. Patients commonly have single to multiple foot pathologies that go undetected. This leads to underdiagnosed foot disorders and delayed medical treatment.

Common patient foot abnormalities include fungal infection of the skin (tinea pedis) and toenails (onychomycosis), secondary bacterial infection (especially fourth to fifth toe web space maceration sites), structural bone irregularities (hallux valgus/bunion, claw toes, etc), signs of neuropathy (hammer/claw toes, dry plantar skin surface), compromised vascularity (arterial or venous) and other causes for edema of the feet/lower limbs.

A previous Healthy Foot Screen validation study was performed to facilitate health care providers in recognizing and treating common foot problems in a timely manner. The development of this easy-to-use, foot screening tool was previously assessed for interrater reliability and validity. Items that were considered valid and reliable in both the right and left foot included: diabetes, smoking, neuropathy, palpable foot pulse, abnormal fourth to fifth toe web space, previous ulcer/amputation, pitting edema, bony abnormality, and dry plantar skin.

The purpose of this pilot study, is to assess this screening tool in an outpatient, community clinical setting with everyday patients.

Methods: A prospective cohort pilot study was conducted on n=120 adult patients, 18 years or older, attending a community dermatology clinic. Patients were excluded from the study if they had a current foot ulcer or entire foot amputations. Consecutive patient convenience sampling was used, and verbal consent was obtained by one of two assessors (K.M. and A.B.). Each patient was examined by one assessor for demographics (age and gender), and items of the screening tool. Data from the screening process was exported from paper to Microsoft Excel by a trained researcher (K.M.).

Results: The 18 item foot screen was positive for one or more items in 74.17% of individuals with only 25.83% having completely low risk feet– no diabetes, no tobacco use, and no screened foot abnormalities. Screened individuals with more than one positive item: 2-4 (37.49%), 5-8 (23.31%), 9 or more (5.82%). Signs of potential fungal foot infections were documented: dry plantar skin 36% (**L**eft/**R**ight), onychomycosis 31-35% (L/R), and macerated toe webs 11-12% (L/R). Diabetes was present in 10-15%, 10% were persons that smoked, and 14-15% (L/R) had potential neuropathy. Five percent had a previous foot ulcer or localized amputation, bony abnormalities were noted in 26-29% (R/L), non-palpable pulses 8-9% (L/R) and pitting edema of the ankle 13-14% (L/R).

Conclusion: A significant majority of consecutively screened adult patients (74.17% in our pilot) entering a clinical setting has one or more foot pathologies, with possible fungal infection in up to 35% of nails (about ½ of abnormal nails are fungal). Implementation of this screening tool has the ability to detect and treat common foot related problems and improve patient outcomes with appropriate referrals. The results of this pilot will help the researchers further develop and refine the final Healthy Foot Screening Tool.

ABSTRACT 19

AN INVESTIGATION OF WOUND SURFACE PH AND BACTERIAL BURDEN

Author(s): Khalad Maliyar, BSc[1]; Dr. R. Gary Sibbald, MD, M.Ed., D.SC (Hon), FRCPC (Med)(Derm), FAAD, MAPWCA, JM[2,3,4]

Affiliation(s): University of Toronto, Faculty of Medicine, Toronto, ON, CAN[1]
Toronto Regional Wound Healing Clinic, Mississauga, Canada[2]
Dalla Lana Faculty of Public Health, University of Toronto, Toronto, Canada[3]
Trillium Health Partners, Mississauga, Canada[4]

Background: Objective local wound infection clinical indicators are necessary to guide healthcare providers to manage wound infection. The pH of skin usually exists in an acidic range, from 4.2-5.6. In contrast, the surface of chronic wounds typically has an elevated alkaline environmental range of 7.2-8.9. It has been documented that wounds with higher pH demonstrate lower rates of healing compared to wounds with pH closer to neutrality. Evidence also supports that a higher wound alkalinity is associated with a more optimal environment for various bacterial species to grow and survive.

Previous work by Sibbald et al. has resulted in a validated clinical tool for diagnosing superficial wound bacterial damage (NERDS criteria – Nonhealing, Exudate, Red Friable tissue, Debris, and Smell). By collating the presence of 3 or more clinical signs of the NERDS criteria (critical colonization), the sensitivity and specificity critical compared to culture results was 73.3% and 80.5% respectively. Recent research has identified pH as an objective clinical parameter that may be associated to critical colonization. The purpose of this study is to assess the association between wound pH and the extent of superficial wound critical colonization using the NERDS guide.

Methods: An ongoing prospective cross-sectional cohort study was conducted with 50 adult patients out of a targeted 100, aged 18 years or older attending the Toronto Regional Wound Clinic. Wound pH was measured using pH indicator strips and wounds were assessed for the presence or absence of clinical signs of bacterial superficial critical colonization using the NERDS clinical criteria.

Results: After wound assessment, it was determined that 20% of patients were positive for at least three out of the five NERDS criteria. Interim results reflect that the average pH of wounds in these patients were 8.65. Eighty percent of patients did not meet the NERDS criteria for superficial critical colonization. The average pH of wounds in these patients were 8.66.

Conclusion: No significant difference in wound bed pH was found in patients who met NERDS criteria for superficial critical colonization, compared to those who did not meet the criteria. The alkaline pH found in these patients is consistent with the literature findings for chronic wounds. However, pH indicator strips may have limited utility as an objective predictor of local wound critical colonization to facilitate a targeted therapeutic approach to wound management. An individual factor analysis of each NERDS criteria may identify a more specific association between individual clinical criteria and wound surface pH.

ABSTRACT 20

UNIQUE PROPERTIES OF OXYGENATED COMPOSITE DRESSING PROVIDES SUPERIOR PRESSURE REDISTRIBUTION

Author(s): Jeffrey A. Niezgoda, MD, FACHM, MAPWCA, CHWS[1], Jonathan A. Niezgoda[2], Amie Franklin, PhD[3]

Affiliation(s): Advancing the Zenith of Healthcare Wound & Vascular Center
Milwaukee, WI, USA

Background: Recent studies [1,2] have suggested the utilization of a variety of foam and silicone dressings for the purpose of mitigating shear, friction and pressure forces in the prevention or mitigation of pressure injury and resultant pressure ulcer formation. This study was designed to test the properties of a novel oxygenated composite dressing and measure its capability to provide pressure forces compared to currently available standard foam and silicone dressings.

Methods: A pressure mapping device (XSensor LX205 – XSENSOR Technology Corporation, Calgary, Canada) was utilized to measure the reduction in pressure forces that were achieved in a variety of standard foam and silicone dressings. The testing was performed using a standardized protocol (1.7kg, 7.5cm sphere) in a controlled environment by the same technician [Photo 1]. A variety of readily available and common clinically used foam and silicone dressing were tested. Additionally, a composite foam dressing with an oxygenated reservoir was also tested. Each study dressing was sequentially tested 3 times in the same order. Digital data output which included Average Pressure (mmHg) [Graph 1], Contact Area (cm2) [Graph 2] and Peak Pressure (mmHg) [Graph 3], and corresponding colorized pressure map images were recorded [Photo 2]. Mathematical analysis of the averaged pressure readings and surface area was performed.

Results: All dressings tested demonstrated reduction of pressure forces as compared to the control (sphere with no dressing interface). The oxygenated composite foam dressing demonstrated the greatest reduction of pressure forces and the greatest surface area of all the study dressings tested [Photo 3]. There was a positive correlation between force dispersion over a greater surface area and a reduction in both Average and Peak Pressure results. The results were significant for both the Allevyn and OxyBand dressing types ($p \leq 0.05$*).

Conclusion: This study confirms that foam and silicone dressings may provide some protection for patients at risk for pressure injury by decreasing pressure forces and dispersing pressure over a greater surface area. A novel oxygenated dressing provided significantly greater pressure reduction in this model. The superior pressure reduction properties may be due to the composite oxygenated reservoir contained in this composite dressing which could improve the clinical benefit achieved when using dressings to mitigate pressure forces in at risk patients.

References:

1. Black J, Clark M, Dealey C, Brindle CT, Alves P, Santamaria N, Call E. Dressings as an adjunct to pressure ulcer prevention: consensus panel recommendations. Int Wound J 2014; doi:10.1111/iwj.12197

2. Call E, Pedersen J, Bill B, Black J, Alves P, Brindle CT, Dealey C, Santamaria N, Clark M. Enhancing pressure ulcer prevention using wound dressings: what are the modes of action?. Int Wound J 2013; doi: 10.1111/iwj.12123

ABSTRACT 21

NOVEL UTILIZATION OF NEAR INFRARED SPECTROSCOPY (NIRS) IMAGING IN DEMONSTRATING THE CLINICAL EFFICACY OF ARTERIAL ENDOVASCULAR INTERVENTION

Author(s): Jonathan A. Niezgoda, MA, Brandon C. Hoffman, BS, Ross L. Rybakowicz, BS, Awais Siddique, MD, Jeffrey A. Niezgoda, MD, FACHM, MAPWCA, CHWS

Affiliation(s): Advancing the Zenith of Healthcare Wound & Vascular Center
Milwaukee, WI, USA

Introduction: There are a variety of technologies that are currently utilized clinically to assess tissue perfusion and oxygenation. The "Gold Standard" has not been established as all technologies have physiologic limitations, operational challenges and cost constraints. Ankle Brachial Index evaluation, Duplex ultrasonography and invasive angiography provide assessment of the macro circulation but all are limited in the ability to directly measure microcirculation and localized skin perfusion. Pulse-oximetry only provides a gross assessment of perfusion by measuring a single and focal site which requires direct contact with the area. Indocyanine green (ICG) has been reported as a modality to measure larger areas, but with this method has not been correlated with meaningful clinical interpretation of tissue perfusion, is associated with significant cost of equipment and is labor intensive. Thermography is at best an estimate of blood flow, not an actual measurement of tissue perfusion. Additionally it does not specifically measure oxygenation, cannot be readily reproduced, and results can be influenced greatly by a number of external factors.
Transcutaneous Oximetry (TCOM) is widely used clinically and has been recognized as a tissue perfusion technology for decades. TCOM is associated with significant variability due technique and tissue characteristics, provides only a very focal measurement, potentially misses islets of hypoxia, and is associated with significant labor costs due to the time required to perform the testing. Near Infrared Spectroscopy (NIRS) imaging is a developing technology that shows promise of resolving many of the problems associated with other perfusion assessment technologies, as it is fast, accurate and provides large area assessment qt a fraction of the cost of other technologies. This presentation explains NIRS and provides a clinical case correlation to illustrate one application of this technology.

NIRS Technology: Near infrared spectroscopic imaging technology has existed for over 20 years but only recently has it been practical and applicable in a healthcare setting. The NIRS imaging device uses flashes of near infrared light to look at the underlying perfusion of oxygen in an area of tissue. On the light spectrum, near infrared light is situated just between visible and infrared light, around 600nm to 1000nm. The NIRS camera captures and measures is how much light is absorbed between this range and the difference between two specific values. At 750nm light is absorbed by unbound hemoglobin and at 850nm light is absorbed by oxygenated hemoglobin. The percentage of oxygen perfusion in these tissues is derived from the difference in these absorption coefficients.
Oxygen perfusion is an amalgamation of the relative measurements of oxygen in capillaries, venules, arterioles. Local oxygen perfusion can be described as interplay between oxygen delivery and oxygen tissue consumption. When oxygen consumption is greater than oxygen delivery it can lead to tissue hypoxia. Lower values of oxygen perfusion can reflect a variety of underlying issues including but not limited to decreased cardiac output, hypoxia, or a hypermetabolic state. Higher levels of oxygen perfusion clinically suggest conditions conducive to healing, but can be a sign of decreased utilization of oxygen caused by a capillary autoregulation error or mitochondrial dysfunction.

Clinical Case Correlation: A 59 year old Caucasian male with a history of diabetes mellitus, atherosclerosis BLE, venous hypertension and insufficiency, ischemic changes to the skin and necrosis of D2 and D3 on the right foot was referred for a vascular consultation, which culminated in endovascular intervention. NIRS imaging was utilized to access the pre and post procedure blood flow in the right extremity. The findings of the NIRS imaging are presented.

Discussion: This case demonstrates the use of NIRS to evaluate the improvement in tissue perfusion and oxygenation following endovascular intervention. NIRS is a fast, non-invasive technology that can enhance clinical assessment of tissue perfusion while decreasing typical labor and equipment related costs. Use of NRIS imaging immediately before and after the procedure provided an interesting and potentially important clinical assessment. Pre-procedure images showed low oxygenation throughout the extremity. Immediately following recanalization the images showed a measurable increase in tissue perfusion and associated oxygenation.

Conclusion: The use of NIRS imaging in a clinical setting is expanding. The ability to have an accurate and immediate representation of macro and micro circulation is unprecedented. NRIS technology may help expedite vascular evaluations, both pre and post interventions, and may compliment clinical management and decision making.

References:

1. Landsman A. S, Barnhart D., Sowa M., Near-infrared spectroscopy imaging for assessing skin and wound oxygen perfusion, Clinics in podiatric medicine and surgery, Volume 35, PP. 343-355, 2018
2. Livingston M., Multispectral oximetry imaging readings with associated healing trajectory. Document on file with Kent Imaging, Available at http://www.kentimaging.com/research-article/

ABSTRACT 22

CAN NEAR INFRARED SPECTROSCOPY (NIRS) REPLACE TRANSCUTANEOUS OXIMETRY IN THE CLINICAL MANAGEMENT OF COMPROMISED WOUND?

Author(s): Brandon C. Hoffman, BS, Jonathan A. Niezgoda, MA, Ross L. Rybakowicz, BS, Jeffrey A. Niezgoda, MD, FACHM, MAPWCA, CHWS

Affiliation(s): Advancing the Zenith of Healthcare Wound & Vascular Center
Milwaukee, WI, USA

Introduction: The management of chronic wounds can be challenging due to the many factors that can contribute to non-healing. The etiology of the wound primarily drives the treatment plan but regardless of the etiology, assessment of a patient's vascular status is critical to the clinical decisions. Many technologies exist to assess a patient's vascular status. Ankle brachial index (ABI) and pulse volume recordings (PVR), are good indicators of the macrovascular status of the patient. Even with sufficient macrovascular blood flow, compromised microvasculature surrounding a wound can play a role in non-healing. Assessment of the microvascular status may include transcutaneous oxygen measurement (TCOM) or skin perfusion pressure, however, imitations of these tests including time, cost, and assessment that is only estimate perfusion. The use of near infrared spectroscopy can eliminate some of these drawbacks.

NIRS Technology: Near infrared spectroscopy is based on the principle that light is absorbed and reflected differently among oxygenated and non-oxygenated hemoglobin. Using computer interfaced algorithms to detect and interpret differences in absorption a model can be created displaying a percentage of oxygenation in the captured area. The technology is reportedly associated with many advantages including decreased time of assessment; reduction of disposable cost compared to TCOM, and being less invasive and burdensome on the patient as compared to undergoing other timely and more invasive screenings. Prior published suggest the use of this technology can enhance the clinician's treatment decisions, guide the use of advanced modalities, and contribute to the prediction of healing in a chronic wound (1).

Methods: A NIRS handheld camera (Kent Imaging, 804B 16 Avenue SW, Calgary, Alberta Canada) was used in this study. We present a case study comparing NIRS to TCOM evaluation to assess tissue perfusion and oxygenation. A 46 year old Hispanic male with DM presented with a non-healing transmetatarsal amputation. NRIS Colorimetric Images of the open wound were obtained before, during, and after the performance of TCOM. NIRS tissue oxygenation measurements were selected at sites immediately adjacent and circumferential to the TCOM electrode and an average value was then calculated. TCOM results and NIRS images and date were compared and are presented.

Results: NIRS colorimetric imaging generated data is displayed and compared to TCOM values. Strong correlation between the assessment methods was identified and is reported. Statistical analysis was not accomplished based on the small sample size, however, our results collaborate and confirm clinical results that has been previously published which demonstrated significant correlation between the technologies (2). Additionally, many other advantages of NIRS were observed including decreased procedural time, less invasiveness to the patient, and evaluation of a wider skin areas as compared to the TCOM study. An islet of tissue hypoxia was identified with NIRS that would have been missed with the TCOM study.

Conclusion: This study confirms prior published results which suggest that NIRS correlates well with TCOM assessment of tissue perfusion and oxygenation. Utilization of NIRS in the wound care clinic could provide added efficiency and cost efficacy in the assessment of the microvascular enhancing clinical decision making. NIRS is a promising emerging technology that will positively contribute to clinical management optimizing patient outcomes.

References:

1. Landsman A. S, Barnhart D., Sowa M., Near-infrared spectroscopy imaging for assessing skin and wound oxygen perfusion, Clinics in podiatric medicine and surgery, Volume 35, PP. 343-355, 2018
2. Livingston M., Multispectral oximetry imaging readings with associated healing trajectory. Document on file with Kent Imaging, Available at http://www.kentimaging.com/research-article/

ABSTRACT 23

THE INCIDENCE OF DIABETIC LOWER EXTREMITY COMPLICATIONS REQUIRING HOSPITALIZATION IN SEVEN COUNTIES OF PA 2010-2016

Author(s): Ronald M Renzi DPM[1], Deep Shah BS[2], Rebecca Van Dyke BS[3], Farhad Foroudi DPM[4]

Affiliation(s): Abington Hospital/Jefferson Health Abington, PA, USA[1]
Temple school of Podiatric Medicine Philadelphia, PA, USA[2]
Temple school of Podiatric Medicine Philadelphia, PA, USA[3]
Chesnut Hill Hospital, Philadelphia PA, USA[4]

Background: Lower extremity complications represent a large share of the overall morbidity caused by diabetes mellitus. Treatment and prevention of diabetic foot infections and possible amputation is a big segment of modern healthcare. The prevalence of these amputations has been found to be higher in communities with low socioeconomic status (SES). This report looks at the incidence of diabetic foot infections or amputations in several similar counties of PA. The relationship of SES to overall lower extremity complications in diabetic patients is explored.

Methods: The PA sate inpatient database was accessed to capture data on all hospitalizations with a diagnosis of diabetic foot infection or diabetic lower extremity amputation for patients residing in seven counties of PA. the incidence of diabetes complications was calculated for each county. The study covered the years 2010 to 2016.

Results: The lower extremity complication rate requiring hospitalization for patients with diabetes increased over time in all seven counties studied. Counties with low SES were found to have higher rates of complications than higher SES communities. This population-based study covered over 2.2 million lives.

Conclusion: Lower extremity amputation from the effects of diabetes have been found to be more common in communities with low SES status. This report suggests that lower extremity complications in patients with diabetes also is related to SES. The rise in incidence of overall lower extremity complications indicates more preventive foot care and education is still warranted. Preventive services should be weighted toward low SES communities.

ABSTRACT 24

INDOCYANINE GREEN ANGIOGRAPHY FOR THE ASSESSMENT OF ISCHEMIC WOUNDS: A GAME CHANGER IN LIMB PRESERVATION

Author(s): Jeffrey A. Ross, DPM, MD, FAPWCA[1]

Affiliation(s): Baylor College of Medicine
Houston, TX

Background: There is a need for the creation of objective, quantifiable, and reproducible parameters for tissue perfusion. To demonstrate the application of Indocyanine Green Angiography (ICGA) in the assessment of tissue and foot perfusion in patients with PAD.

With these parameters, and with the use of Inocyanine Green Angiography (ICGA) , the surgeon can determine the need for and success of revascular procedures, and in determining levels of amputation /closure as well as wound management.

Methods: Risk stratification, based on three major factors that impact amputation risk and clinical management: Wound, Ischemia, and Foot Infection (WIfI) was utilized prior to revacularization and surgical intervention of the foot. With real time perfusion visualization, the clinician can give patients instant feedback about the diagnosis and treatment of the wound. The use of the Inodcyanine Green Angiography can help determine whether there is adequate blood flow, and make informed decisions in regards to the best treatment in each individual case for the best healing outcome. Intra-operatively, ICGA imaging can provide objective quantifiable, and reproducible parameters of perfusion that can aid in determining the level of debridement or amputation in the foot

Results: The Inocyanine Green Angiography was utilized post endovascular procedures as a tool to assess perfusion to certain areas of the foot, pre-operatively. The fluorescence intensity is viewed in a grey scale with a greater white indicative of higher intensity. The heat map mode is used, where red indicates higher intensity, and blue, lower intensity. The quantifiable data can then be utilized to make an informed decision as to the level of amputation to be performed, and to assess flaps that will be viable for potential closure. Case presentations will demonstrate the use of the Indocyanine Green Angiography and their outcomes, in conjunction with the use of intermediary skin substitutes and Negative Pressure Wound Therapy.

Conclusion: Utilizing Inocyanine Green technology, intra-operative fluorescence angiography provides a minimally invasive tool to help determine tissue viability and perfusion to the extremities. The Indocyanine Green Angiography can be useful as a surgical planning option for the surgeon and informative tool for the patient.

The Indocyanine Green technology can help predict which tissues are viable (flaps), vs. those at risk lacking adequate perfusion. This can help determine at which level an amputation can be performed, and how well the closure site(s) will heal.

References:

1. Norgren I, Hiast WR, Donnandy JA, Nelder MR, Harris KA,Fowkes PG, Inter Society Concerns for the Management of Peripheral Arterial Disease . Eur J. Vas Endovascular Surg 2007, 33 (suppl 1(51-75).

2. Ouriel K. Peripheral Arterial Disesae, Lancert 2001; 358:1257-64.

3. Suggested standards for reports dealing with lower extremity ischemia. Prepared by the Ad Hoc Committee on Reporting Standards, Society for Vascular Surgery/North American Chapter, International Society for Cardiovascular Surgery. J Vasc Surg 1986, 4 90-94.

4. Fontaine R, Kam R, Kacey R. (Surgical treatment of peripheral circulation disorders), Helv Chir Acta, 1954;21499-533.

5. Braun JD, Trinidad-Hernandez M, Perry D. Armstrong DG, Mills Js L. Early quantitative evaluation of indocyanine green angiography in patients with critical limb ischemia. J Vasc Surg 2013; 1213-1218.

6. Jamieson C., The definition of critical ischemia of a lower limb. Br J. Surg, 1982; 69 Suppl 5.

7. Carter SA. The definition of critical ischemia of the lower limb and distal systolic pressures. Br J. Surg 1983; 70; 188-9

8. Boulton AJ, Armstrong DG, Albert SF, Frykberg RG, Hellman R, Karlman MS, et al. Comprehensive foot examination and risk assessment: a report of the task force of the foot care interest group of the American Diabetes Association, with endorsement by the American Association of Clinical Endocrinologists. Diabetes Care 2008; 31:1679-85.

9. Ballard JL, Elke CC, Brent TJ, Kileen JD, A prospective evaluation of transcutaneous oxygen measurements in the management of diabetic foot problems. J. Vasc Surg 1995;22385-90 discussion490-2.

10. Lepow BD, Perry D, Armstrong D. The Use of SPY Intra-operative Vascular Angiography as a Predictor of Wound Healing Podiatry Management 141-148, August 2011.

11. The Society for Vascular Surgery Lower Extremity Threatened Limb Classification System: Risk stratification based on Wound, Ischemia, and Foot Infection (WIfI), J. Vascular Surgery, Oct 14, 2013 (on Line)

ABSTRACT 25

HIGH BACTERIAL ROAD IMPAIRS CELL PROLIFERATION IN THE GRANULATION TISSUE OF PRESSURE ULCERS

Author(s): Tomoya Sato[1], MD; Takahiro Abe[2], MD, PhD, Shigeru Ichioka[1], MD, PhD

Affiliation(s): Department of Plastic and Reconstructive Surgery, Saitama Medical University, Saitama, Japan[1]
Department of Oral and Maxillofacial Surgery, The University of Tokyo, Tokyo, Japan[2]

Background: Granulation tissue formation is an important rate-limiting step in wound healing. Although several risk factors of delayed wound healing have been reported, the specific factors responsible for the impairment of cell proliferation in the granulation tissue of wounds remain unknown. We aimed to assess the factors that impair cell proliferation in the granulation tissue of pressure ulcers using immunohistochemistry for the cell proliferation marker Ki-67.

Methods: This was a single center, cross-sectional study. The study included 86 patients with stage III or IV pressure ulcers. Two granulation tissue biopsy specimens were obtained from 86 patients. The specimens were used for histological examination, Ki-67 immunohistochemistry, and bacterial count assessment. The percentage of Ki-67-stained cells was considered as the Ki-67 index. Pearson's product-moment correlation coefficient (r) was used to assess the relationship between the Ki-67 index and other quantitative variables, including age, body mass index, bacterial count (Log10 CFU/g), serum albumin level, hemoglobin level, white blood cell count, and C-reactive protein level. The Mann–Whitney *U* test was used to compare the mean Ki-67 index according to sex, diabetes, smoking status, and wound culture. Univariate and multivariate linear regression analyses were used to assess the association between the Ki-67 index and other parameters. All statistical analyses were performed using SPSS version 22 (IBM Corp., Armonk, NY).

Results: The Mann–Whitney U test revealed that the bacteria-positive group had a lower Ki-67 index ($p = 0.045$). Bacterial count demonstrated a significant negative correlation with the Ki-67 index ($r = -0.325$, $p = 0.002$). There was no significant relationship between the Ki-67 index and other quantitative values. Univariate linear regression analysis showed that bacterial count was a significant predictor of the Ki-67 index . The unadjusted β-coefficient was −1.02 (95% confidence interval, −1.66 to −0.37, $p = 0.002$). Other factors were not associated with the Ki-67 index. Multivariate linear regression analysis showed that bacterial count was a significant predictor of the Ki-67 index (Table 1). The adjusted β-coefficient was −1.34 (95% confidence interval, −2.01–−0.66, $p < 0.001$).

Conclusion: The present study found a correlation between the Ki-67 index and bacterial count. Regression analysis demonstrated that bacterial count was a significant predictor of poor cell proliferation. These results suggest that granulation tissue formation in pressure ulcers may be accelerated if high bacterial load is reduced appropriately.

Table 1. Multivariate linear regression coefficients to predict the Ki-67 index

Variable	Coefficient	Standard error	95% CI	*P*-value
Intercept	11.7	9.14		
Age	–0.37	0.05	–0.14 to 0.06	0.46
Sex	1.44	0.22	–2.04 to 4.93	0.41
Body mass index	–0.19	0.22	–0.63 to 0.25	0.39
Diabetes	1.50	1.89	–2.26 to 5.27	0.43
Current smoking	–0.92	1.79	–4.49 to 2.64	0.61
Bacterial count (Log_{10} CFU/g)	–1.34	0.34	–2.01 to –0.66	<0.001
Serum albumin, g/dL	2.36	2.21	–2.04 to 6.77	0.29
Hemoglobin, g/dL	–0.77	0.40	–1.56 to 0.03	0.06
WBC count, $\times 10^3$/μL	0.01	0.00	0.00 to 0.02	0.06
CRP, mg/dL	–0.32	0.29	–0.91 to 0.26	0.28

WBC, white blood cell; CRP, C-reactive protein

ABSTRACT 26

COMPREHENSIVE INTERPROFESSIONAL ASSESSMENTS IMPROVED WOUND RELATED DIAGNOSES AND HEALING TRAJECTORY FOR HOME CARE PATIENTS WITH STALLED COMPLEX CHRONIC WOUNDS

Author(s): Dr. R. Gary Sibbald[1,2,3], James A. Elliott[1], Dr. Morgan Lim[4,5], Dr. Reneeka Persaud[1], Laurie Goodman[6], Dr. Ranjani Somayaji[7]

Affiliation(s): Toronto Regional Wound Healing Clinic, Mississauga, Canada[1]
Dalla Lana Faculty of Public Health, University of Toronto, Toronto, Canada[2]
Trillium Health Partners, Mississauga, Canada[3]
Trillium Health Partners, Institute for Better Health, Mississauga, Canada[4]
Institute of Health Policy, Management and Evaluation, University of Toronto, Toronto, Canada[5]
Humber River Hospital, Toronto, Canada[6]
Cumming School of Medicine, University of Calgary, Calgary Canada[7]

Background: Chronic wounds are becoming more common due to an aging population and increasing prevalence of risk factors including diabetes, obesity, and peripheral vascular disease. Chronic wounds are difficult to heal and their healing trajectory can become stalled. Improved diagnoses help identify the ability of the wound to heal, while simultaneously improving treatment outcomes. This study evaluated the effect of comprehensive interprofessional wound assessments on diagnoses in an Ontario Canada population living with stalled complex chronic wounds.

Methods: This retrospective cohort study reviewed patients with stalled complex chronic wounds who were referred from the local government home care coordination organization. Patients underwent a comprehensive interprofessional assessment between February 2013 and September 2014 at an interprofessional ambulatory wound clinic. A chart review collected clinical and demographic data via a case report form. Outcomes assessed included improved wound diagnoses and a record of the healing status of the wound i.e. if the wound was healable, maintenance, or non-healable. Analysis was conducted using SPSS Version 22 (IBM).

Results: A total of 318 patients (54.0% male), mean age 59 years were included for analysis. Patients were not in a healing trajectory before assessment. Hypertension, obesity, diabetes, dyslipidemia, peripheral vascular disease and heart disease were common comorbidities. More accurate diagnoses were made in 263 patients (82.7%). Intake patient wound diagnosis remained unchanged in only 55 patients (17.3%). After comprehensive interprofessional assessment 100% of patients (n=318) had the healing status of the wound determined vs. 36.0% beforehand. A healing trajectory was established for 58% of clients 4 weeks post assessment.

Conclusion: Patients with complex chronic wounds have multiple co-morbidities. These patients often lack accurate wound related diagnoses and ability of their wounds to heal is often not determined before initiating treatment. These assessment gaps likely delay healing and impair optimal healthcare resource use. Team based interprofessional care should be viewed as a necessity for wounds not healing at the expected rate. Interprofessional care requires a coordinated and integrated approach from all stakeholders.

Key Words: home care, chronic wounds, interprofessional, ulcers, diagnosis

ABSTRACT 27

CHRONIC COMPLEX LEG ULCER RETROSPECTIVE REVIEW WITH A COMPREHENSIVE INTERPROFESSIONAL ASSESSMENT RESULTING IN IMPROVED WOUND HEALING TRAJECTORY

Author(s): Dr. R. Gary Sibbald[1,2,3]; Luvneet Verma[1,4], James Elliott[1], Dr. Reneeka Persaud-Jaimangal[1], Laurie Goodman[7], Dr. Ranjani Somayaji[8], Dr. Morgan Lim[5,6]

Affiliation(s): Toronto Regional Wound Healing Clinic, Mississauga, Canada[1]
Dalla Lana Faculty of Public Health and Faculty of Medicine, University of Toronto, Canada[2]
Trillium Health Partners, Mississauga, Canada[3]
University of Ottawa Faculty of Medicine, Ottawa, Canada[4]
Trillium Health Partners, Institute for Better Health, Mississauga, Canada[5]
Institute of Health Policy, Management and Evaluation, University of Toronto, Canada[6]
Humber River Hospital, Toronto, Canada[7]
Cumming School of Medicine, University of Calgary, Calgary Canada[8]

Background: An estimated 1 in 100 people will develop a leg ulcer in their lifetime. A more accurate/precise diagnosis may improve healing outcomes and decrease healthcare system resource utilization for patients with leg ulcers.

Methods: A retrospective cohort study assessed patients with complex chronic wounds, including leg ulcers, referred from a regional home care coordination organization. Patients underwent a comprehensive interprofessional assessment (CIA) between February 2013 and September 2014 at the Toronto Regional Wound Healing Clinic. A chart review collected clinical and demographic data. Outcomes assessed included accuracy/precision of wound diagnosis and if wounds had been assessed for the ability to heal.

Results: In total 123 patients with leg ulcers were referred for comprehensive interprofessional assessment (CIA). Of these, 55% (n=68) patients were male and 59%% (n=73) of patients were overweight or obese. Prior to CIA, only 23% (n=28) of wounds were assessed for the ability to heal. Subsequent to CIA, all patients had a healability assessment with 66% (n=81) of wounds being classified as healable, 28% (n=34) as maintenance and 6% (n=8) as non-healable. Only 10% (n=12) of patients had no change in diagnosis with 90% of patients (n=111) receiving a more accurate/precise diagnosis.

The interprofessional team referrals from home care did not diagnose the 10 inflammatory ulcers (e.g., pyoderma gangrenosum, Vasculitis, vasculopathy), 8 deep infections or any of the skin cancers that presented with an ulcer. Leg ulcer patients also have multiple co-morbidities (critical colonization, deep and surrounding infection, persistent inflammation) that were not previously diagnosed and may require treatment to optimize healing. Realistic clinical outcomes are determined with a healability assessment (healable, non-healable, maintenance) that optimize resource utilization and outcomes that was categorized in an additional 77% of patients.

Conclusion: Leg ulcer patients receiving home care often lack three key diagnostic components that would facilitate wound healing (vascular status, additional diagnosis, co-morbidity/complicating factors). Treatment can only be optimized with an accurate/precise vascular status classification (e.g. venous ulcers with coexisting arterial disease require an arterial disease management and modified compression when indicated). There may be a more accurate diagnosis that is more important than the vascular status (e.g. pyoderma gangrenosum) that has not been recognized prior to the CIA. Team-based interprofessional wound care should be viewed as a necessity with improved outcomes for complex wound care patients.

ABSTRACT 28

ACOUSTIC PRESSURE SHOCKWAVES: A NOVEL ADVANCED THERAPY FOR WOUND MANAGEMENT

Author(s): Robert J. Snyder, DPM, MSc, CWS, FFPM RCPS (Glasg)[1]

Affiliation(s): Professor and Director of Clinical Research
Director, Fellowship Program in Wound Healing and Clinical Research
Barry University, Scholl of Podiatric Medicine, Miami Shores, FL, USA[1]

Background: The dermaPACE® System (SANUWAVE Health, Inc., Suwanee, GA, USA) is based upon SANUWAVE's proprietary Pulsed Acoustic Cellular Expression (PACE®) Technology. PACE® is the newest generation of shockwave technology utilizing electrohydraulic shockwave principle, exhibiting beneficial wound healing effects of acoustic pressure focused shockwaves. Level I clinical evidence shows that PACE® technology elicits a cellular response and consequently revascularization and tissue growth in chronic wounds. The dermaPACE® System is FDA cleared for the treatment of Diabetic Foot Ulcers (DFUs) in the U.S. and is CE Marked in the E.U.

Methods: The dermaPACE® System was evaluated under two studies (IDE G070103, US FDA) for advanced treatment of DFUs. The studies were designed as prospective, randomized, double-blind, parallel-group, sham-controlled, multi-center 24-week studies at 39 centers. A total of 336 subjects were enrolled and treated with either dermaPACE® System plus conventional therapy or conventional therapy (a.k.a. standard of care) alone. The study allowed up to eight (8) device applications (4 within the first two weeks of randomization, and 1 treatment every two weeks thereafter up to a total of 8 treatments over a 10-week period). The primary objective was to compare the rates of complete wound closure between the two arms.

Results: The combined data shows that the statistical significance ($p \leq 0.050$) for complete wound closure in favor of the dermaPACE® System was achieved at the 20-week time-point and was maintained through the end of the study. At the 20-week endpoint, the rate of wound closure in the dermaPACE® cohort was 35.40% compared to 24.39% for the control group (p=0.027). At the 24-week endpoint, the rate of wound closure in the dermaPACE® cohort was 37.80% compared to 26.20% for the control group (p=0.023).

The mean wound area reduction for dermaPACE® subjects at 24 weeks was 1.92 cm^2 compared to 0.16 cm^2 in the control group. There was a statistically significant difference between the wound area reductions of the two cohorts from the 6-week follow up visit (p=0.003) through the end of the study (p=0.047).

At 4, 12, and 24 weeks, the dermaPACE® group has a higher percentage of subjects with a 50% wound reduction compared to the control (p=0.0581, p=0.0554 and p=0.0899, respectively), all demonstrating a trend towards statistical significance.

In sub-group analyses, statistical significance was achieved in subjects whose height was greater than 70 inches (p=0.0002), weight less than 220 lbs. (p=0.063), have a Body Mass Index (BMI) less than 32 (p=0.006), and Hemoglobin A1C (HbA1C) level greater and equal to 7% (p=0.021).

Conclusion: The dermaPACE® System represents a novel technology in the portfolio of advanced therapies for wound management. This new technology is safe, there was no statistical significance between the two cohorts in treatment-emergent adverse events (55.80% vs. 51.20%), device-related treatment emergent adverse events (5.20% vs. 2.40%), or all adverse events (73.20% vs. 68.90%). The dermaPACE® System is efficacious in healing difficult to heal wounds, has a partial amputation rate of 2.30%, and the recurrence rate of 7.70%.

ABSTRACT 29

REGENERATION OF FULL THICKNESS HAIR-BEARING SKIN IN CHRONIC REFRACTORY WOUNDS WITH AN AUTOLOGOUS HOMOLOGOUS SKIN CONSTRUCT: PRECLINICAL AND CLINICAL EXPERIENCE

Author(s): Nikolai Sopko1 , Naveen Krishnan1 , Georgia Yalanis1 , Devin Miller1 , Nick Baetz1 , Ryan Mathis1 , Pratima Labroo1 , Caroline Garrett1 , Edward Swanson1 , Maurice Nahabedian1.2 , Stephen Milner1 , Mark Granick3

Affiliation(s): PolarityTE, Inc. 1960 S 4250 W, Salt Lake City, UT, USA[1]
National Center for Plastic Surgery, 7601 Lewinsville Rd #400, McLean, VA, USA[2]
Rutgers New Jersey Medical School, Department of Surgery, 185 W S Orange Ave, Newark, NJ, USA[3]

Background: Acute and chronic wounds are a substantial burden on patients and health care systems worldwide. The standard of care for large cutaneous defects is split-thickness skin grafting (STSG), which has significant limitations including donor site morbidity, wound contraction, and lack of dermal appendages including hair and sweat glands. SkinTE, a recently commercialized autologous homologous skin construct (AHSC) product, limits the donor site harvest requirement to a few square centimeters and utilizes the patient themselves to expand and regenerate full-thickness skin across the wound surface.

We sought to evaluate the technology in a preclinical full-thickness skin injury porcine model. In addition, we present the first clinical case of SkinTE in the treatment of a large, non-healing lower extremity wound that failed two prior STSGs.

Methods and Results: Preclinical evaluation was performed using a porcine model. Full thickness cutaneous wounds were covered with the AHSC generated from autologous porcine skin and dressed similar to a split-thickness skin graft. Neodermal expansion was monitored with macroscopic stereoscopic digital photography for up to 120 days. Treated wounds were compared to native skin and non-treated control wounds that were allowed to heal by secondary intention. Harvested tissue histomorphology was assessed with H&E, Masson's trichrome, Periodic Acid-Schiff, immunofluorescent confocal microscopy, and scanning electron microscopy. Clinical evaluation of SkinTE was performed on a 31yo man who had a large chronic, non-healing right lower leg wound resulting from a motorcycle injury 24-months prior that failed two STSGs. Two days before wound debridement, a small, elliptical full-thickness skin harvest was taken from the patient's groin in clinic and shipped overnight to PolarityTE's SkinTE manufacturing facility in Salt Lake City, UT. The harvest site was closed primarily. The harvest was processed and returned to the provider. SkinTE was applied to a 22 cm x 9 cm (198 cm2) debrided area of the right lower extremity and dressed with an occlusive, non-adherent, non-absorbent silicone dressing reinforced with bacitracin and xeroform and changed weekly. The patient was discharged home the same day. Wound healing was monitored with digital photography for 6 months, at which timepoint 2-point discrimination and bioimpedance of the regenerated area was compared to native skin.

Conclusion: Preclinical studies demonstrated significant contraction of control wounds in contrast with AHSC treated wounds, which had restoration of hair-bearing full-thickness skin. Clinical application in a patient demonstrated consistent outcomes. Tissue analysis showed recapitulation of epidermis, dermis, and subdermal fat with dermal appendages including hair follicles and sweat glands, and significantly reduced collagen deposition. Serial photography of the patient's wound demonstrated regeneration of full-thickness hair-bearing skin with pigment regeneration, decreased pain, increased sensation, improved functional and aesthetic outcomes with minimal contracture and scarring. Sensory analysis demonstrated no significant difference in 2-point discrimination between SkinTE and native skin ($p = 0.076$). Bioimpedance analysis of SkinTE regenerated skin relative to native skin showed no significant difference in the moisture, oil, or pliability. These data support the ability of SkinTE to treat complex large chronic wounds.

ABSTRACT 30

PREDNISONE EFFECTS ON POST-LATERAL MALLEOLAR FRACTURE OPEN WOUND, LIMB SALVAGE AND WOUND HEALING

Author(s): Chloe E. Starr, BS; Mark C Domanski, MD

Affiliation(s): N/A

Background: Corticosteroids remain the only proven treatment for giant cell arteritis and are known to interfere with various stages and mechanisms of wound healing, influencing the risk of wound infection and enhances wound healing delay. By the end of this poster, the reader will be able to describe a case were steroids prevented wound healing. Faced with similar clinical situations, the reader will consider decreasing or stopping steroids as a way to achieve wound healing.

Methods: We describe a case of a 76-year-old female patient with an infected, open, lateral malleolar fracture with exposed hardware. The patient was also being treated with 35 mg/day oral prednisone for giant cell arteritis. The patient underwent debridement and placement of a bilayer wound matrix*. The procedure failed. Prednisone was discontinued, and the exact same surgery was repeated. Health granulation tissue successfully covered the exposed bone.

Results: The patient's wound, co-morbidities, and general state of health between the two procedures were similar. The patient thus serves her own control, demonstrating a clinical example of how steroids impede wound healing.

Conclusion: The risks of discontinuing steroids must

ABSTRACT 31

ACELLULAR FISH SKIN PREVENTS RE-INFECTION AND AMPUTATION IN EXPOSED BONE LOWER EXTREMITY WOUNDS WITH HISTORY OF MRSA AND CHRONIC OSTEOMYELITIS

Author(s): Christopher Winters DPM[1]

Affiliation(s): American Health Network, Indianapolis, USA[1]

Background: Chronic osteomyelitis is the most common cause of amputations in DFUs. A novel approach to reduce the risk of re-infections was tried combining a treatment with topical antibiotics in a sponge and fish skin graft* rich in Omega3 to speed up the healing process.

Methods:
1: 65 y.o. diabetic male with transmetatarsal amputation wound and osteomyelitis. Unresponsive to topical collagen dressing†. Treated with fish skin graft* and chitosan sponge# & impregnated with vancomycin and tobramycin.

2: 68 y.o. non-diabetic male. Initial presentation with infected ulcer on his left heel and exposed bone with calcaneal osteomyelitis and maggots. Partial calcanectomy in O.R. Treated with fish skin graft* and chitosan sponge# with vancomycin.

3: 70 y.o. male initial presentation with exposed bone and wagner 3 ulcer medial and lateral side of 3rd toe left foot. History of MRSA. Debrided bone in OR, chitosan sponge# with vancomycin and applied fish skin graft. The infection cleared completely after one debridement in the OR.

Results:
1. Healed in 20 weeks after with 6 applications of fish skin graft* and no incidence of reinfection

2. Healed in 12 weeks with 2 reapplications (3 total) of fish skin graft*, no instances of reinfection.

3. Healed in 20 weeks after 1 further fish skin graft application, later had a BKA due to an unrelated issue.

Conclusion: The unique benefits of the Omega3 rich fish skin grafts* can be used to initiating tissue regeneration and at the same time form a barrier to protect the wound from re-infections.

Trademarked Items:
* Kerecis™ Omega3 by Kerecis
# Sentrex BioSponge by Bionova Medical
† Primatrix by Integra

NOTES

Join Us Next Year

18th ANNUAL NATIONAL CLINICAL CONFERENCE

Baltimore, MD
September 5-7, 2019

139B James Comeaux Rd, Ste 555
Lafayette, LA 70508
337.541.2240 apwca.org